



# AO Reconstruction Plate as Buttressing for Greater Trochanter in Hemiarthroplasty Procedure

Luthfi Hidayat<sup>1</sup>, Aditya Fuad Robby Triangga<sup>1</sup>, Aristida C. Putro<sup>1</sup>, Rahadyan Magetsari<sup>1</sup>

<sup>1</sup>Department of Orthopaedic and Traumatology, Dr. Sardjito General Hospital / Faculty of Medicine, Universitas Gadjah Mada, Yogyakarta

## ABSTRACT

**Background:** There has been an increase in incidence of intertrochanter fractures experienced by elderly population, resulting in the rise of difficult cases with severe damage. Accordingly, the aim of stable fixation in these fractures is designed with appropriate surgical procedures and patient care. The contribution of a stable fixation is due to several considerations including fracture shape and assurance, bone quality, comminution pattern, implant choice, and surgical technique. This study aimed to assess the functional outcomes of the patients with an intertrochanteric fracture who underwent hemiarthroplasty with AO recon as buttressing.

**Material and Methods:** This was a case series study conducted in Gadjah Mada University Academic Hospital in Yogyakarta from January 2019 – November 2019. Patients with Evans unstable intertrochanteric femoral fractures who underwent simultaneous bipolar hemiarthroplasty and fixation with AO reconstruction plate and SS wire as buttressing were evaluated. Pre and postoperative radiographs, postoperative Visual Analog Scale (VAS) score, walking ability using Harris Hip Score (HHS), and Lower Extremity Functional Score (LEFS) were the outcome parameters.

**Results:** A total of 6 patients, 4 of whom were male with an average age of 81 years old were included in this study. All the mechanisms of injury were low-energy trauma. The mean VAS score was decreased, from 7 pre-operatively to 1.5 post-operatively at final follow-up (p-value < 0.05). The patients had a mean HHS of 82.5 and a LEFS mean of 56.7.

**Conclusion:** Buttress plate fixation using an AO reconstruction plate for trochanteric fracture following bipolar hemiarthroplasty resulted in a good functional outcome.

**Keywords:** Hemiarthroplasty, AO reconstruction plate; intertrochanteric fracture, functional outcome

**Level of Evidence : Descriptive study, level III**



This is an open access article under the CC-BY-SA license.

## Article History

Submission : December 20<sup>th</sup>, 2020

Revision : July 13<sup>th</sup>, 2021

Accepted : December 23<sup>rd</sup>, 2021

## Corresponding Author

Luthfi Hidayat, MD

Department of Orthopaedics and Traumatology,  
Dr. Sardjito General Hospital / Universitas Gadjah Mada. Jalan Kesehatan no. 1, Yogyakarta 56281, Indonesia.

Email : [luthfi.hidayat@ugm.ac.id](mailto:luthfi.hidayat@ugm.ac.id)

## Introduction

The elderly population faces an increasing incidence of intertrochanteric fractures of the femur, especially for the comminuted type of fracture. Complications and mortality are considerably higher due to patients' advanced age and a large number of risk factors. Consistent with these additional risk factors, suitable fracture management is required.<sup>1</sup> It is widely accepted that stable internal fixation as soon as possible is the main treatment for intertrochanteric fractures. Since the load stress location acts mechanically, stable fixation is the main factor that leads to the successful treatment of trochanteric fractures. Bone quality, fragment pattern, reduction technique, implant design, and the placement of implants are some variables that determine the strength of fracture fragment-implant configuration.

The reduction and fixation of trochanteric fragments are difficult because the abductor muscles and iliopsoas muscles insert into the trochanters. Since several muscles that attach to the trochanters play an important role in preventing dislocation postoperatively, the reduction and fixation of these fragments should be optimally achieved to maintain stability and walking ability.<sup>1</sup>

This study aimed to evaluate the functional outcome of the AO reconstruction plate as a buttressing plate for greater trochanter stability in the hemiarthroplasty procedure.

## Material and Methods

This research was a descriptive study with a cross-sectional design. The subjects of this study were men and women with the diagnosis of Evans unstable close intertrochanteric fracture with an age range from 65–85 years old.

This study retrospectively reviewed six patients with intertrochanteric fracture of femur patients who underwent bipolar hip arthroplasty with cementless stem and AO reconstruction plate for the repairment of trochanteric fracture fragments from January 2019 – November 2019 in Gadjah Mada University Academic Hospital in Yogyakarta, Indonesia.

The data were collected by evaluating questionnaires and also functional outcomes by using Harris Hip Score (HHS) and Lower Extremity Functional Score (LEFS). The HHS is a score for assessment of the results of hip surgery and is used to evaluate various hip disabilities and methods of treatment.

Patients were interviewed in the range of follow-up from 3 months – 1 year after the surgery.

## Results

A total of 6 patients, 4 of whom were male with an average age of 81 years old were included in this study as seen in Table 1.

**Table 1:** Demographic data of the patients

Patient Demographic	Female (n = 2)	Male (n = 4)	Total (n=6)
Age (yr)	(82)	(80)	(81)
Mechanism of injury			
Low energy trauma	2	4	6
High energy trauma	0	0	0
VAS score at admission	(5.5)	(5)	(5.25)

All the mechanisms of injury were low energy trauma. All the intertrochanteric fractures were classified as Evans unstable

fractures that have posteromedial complex complex instability. All patients have low bone quality.

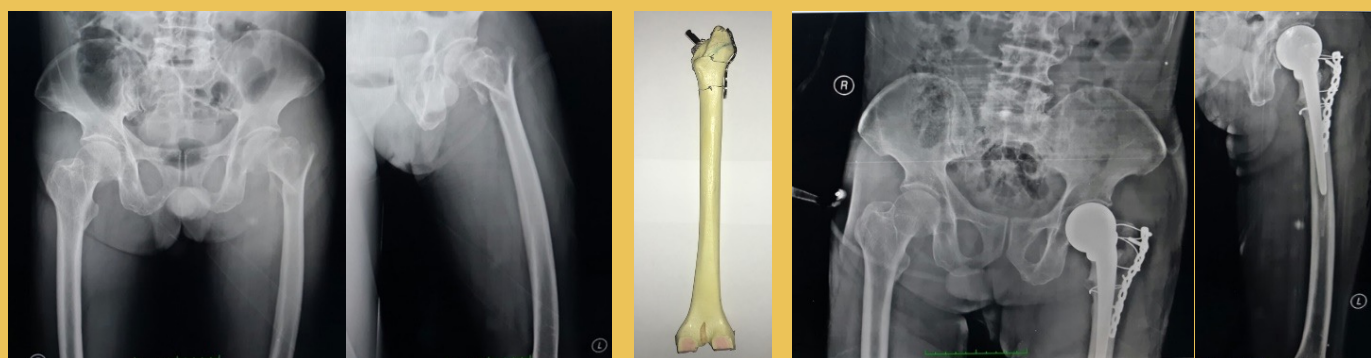
**Table 2:** Functional outcome post-operatively

Outcome	Female (n = 2)	Male (n = 4)	Total (n=6)
HHS	(83.5)	(82.25)	(82.5)
LEFS	(59)	(55.25)	(56.5)
Post-operative VAS Score	(1.5)	(1.5)	(1.5)

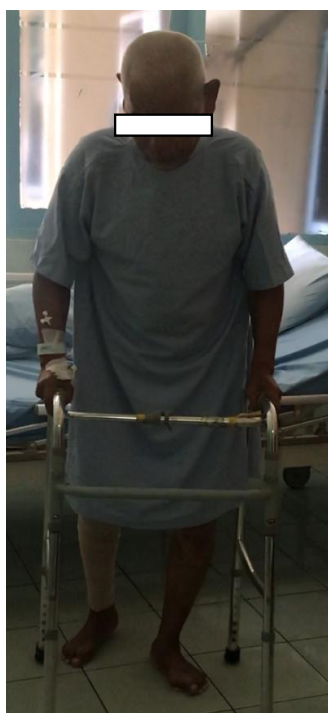Since the patients' initial visit to the hospital, the mean VAS score was significantly reduced from 5.25 pre-operatively to 1.5 post-operatively during follow-up. The patients' outcomes could be seen in Table 2. The mean HHS of 82.5 and a LEFS mean of 56.5

were observed at the time of the evaluation.

The functional outcomes of the patients who were treated by hemiarthroplasty that was enhanced by AO reconstruction are considered good according to LEFS and HHS. No significant post-operative pain was observed.



**Figure 1.** Pre-operative and post-operative anteroposterior and lateral view X-rays of the patients



**Figure 2.** Post-operative outcome of a patient on day 3

## Discussion

Intertrochanteric fractures in the elderly are correlated with high mortality and morbidity. The results of various treatments are still inconsistent. Some studies stated that 1-year mortality rate of elderly intertrochanteric fractures treated with hemiarthroplasty ranged from 12.2% to 35%.<sup>2,3</sup>

The post-operative report of the Harris Hip score shows a good result with a mean of 82.5. This score was the same as the results of other studies that used PFNA post-operatively according to the research conducted by Xiangping et al.<sup>4</sup>

Intertrochanteric fractures with an unstable pattern have more technical difficulties than bipolar hemiarthroplasty compared with a femoral neck fracture. Restoration of deficiency in the length of the leg is difficult due to the landmarks for the -

the restoration of leg length which are the greater and lesser trochanters are not in normal anatomical positions. Gluteus minimus and gluteus medius attach to the greater trochanter for abduction. Persistent pain with the unstable fixation of these muscles and abnormal gait such as Trendelenburg gait may occur because the centrum of the femoral head becomes unable to serve as a lever of the abductor muscle. Despite these technical difficulties, leg length reconstruction is an important aspect that leads to stabilization of implant and post-operative ambulation.<sup>1,5</sup>

Stability is considered another problem to overcome although the use of stem implants that are strengthened by cement is already common.<sup>6</sup> One study concluded that the use of cement should be limited due to mortality risk from cement embolism, fat embolism, and vasodilatation due to autonomic reflex especially in the patient with concomitant cardiovascular disease.<sup>7</sup> One study on trochanteric osteotomy initiated the technique of greater trochanter wiring fixation. The study reported a non-union rate of 4.9% after trochanteric osteotomy and recommended using two wires or more to achieve stable fixation.<sup>8</sup> To overcome the lack of abductor muscle strength, a strong stable fixation is required.

Other studies using a cable plate for the stability of the calcar had significantly reduced the risk of dislocation, abductor weakness, and trochanteric non-union.<sup>9</sup> A wire with a size of more than 1.5 mm was used and wiring techniques with 2 or more were combined depending on fracture patterns and severity. The results of only 2 cases (2.9%) with non-union were observed. The clinical outcomes were considered relatively satisfying.<sup>10</sup>

The more unstable the fracture, especially in comminuted fractures, the greater the difficulty of reduction. This could lead to failure of reduction which will ultimately lead to a higher rate of complications.<sup>11</sup>

It has been reported that to reduce these problems, techniques using trochanter buttressing plates can be applied. These techniques prevent excessive impaction, rotational, and angular distortion.<sup>12,13</sup>

Internal fixation of unstable intertrochanteric fractures in the osteoporotic bone of elderly patients is relatively challenging. There are problems associated with this technique, such as excessive collapse, loss of fixation, and cut-out of the lag screw resulting in poor function. These challenges make the need to add buttresses such as wire or plate.<sup>14</sup>

The AO reconstruction plate acts like a wire and as a buttress. It gives stability to the posteromedial cortex that was lost because of the mechanism of the trauma as stated in a previous study.

Some modifications can be applied to enhance the findings of this study. Intertrochanteric fracture is a rare type of unstable fracture, thus only a small number of cases can be included in this study. A larger, prospective, and comparative study can add further confirmation of these findings.

### Conclusion

Good functional outcome was obtained with buttress plate fixation using an AO reconstruction plate for unstable trochanteric fractures following bipolar hemiarthroplasty.

### References

1. Lee J-M, Cho Y, Kim J, Kim D-W. Wiring Techniques for the Fixation of Trochanteric Fragments during Bipolar Hemiarthroplasty for Femoral Intertrochanteric Fracture: Clinical Study and Technical Note. *Hip Pelvis*. 2017;29(1):44. doi:10.5371/hp.2017.29.1.44
2. Kim GM, Nam KW, Seo KB, Lim C, Kim J, Park YG. Wiring technique for lesser trochanter fixation in proximal IM nailing of unstable intertrochanteric fractures: A modified candy-package wiring technique. *Injury*. 2017;48(2):406-413. doi:10.1016/j.injury.2016.11.016
3. Lee YK, Ha YC, Chang BK, Kim KC, Kim T young, Koo KH. Cementless Bipolar Hemiarthroplasty Using a Hydroxyapatite-Coated Long Stem for Osteoporotic Unstable Intertrochanteric Fractures. *J Arthroplasty*. 2011;26(4):626-632. doi:10.1016/j.arth.2010.05.010



4. Luo X, He S, Zeng D, Lin L, Li Q. Proximal femoral nail antirotation versus hemiarthroplasty in the treatment of senile intertrochanteric fractures: Case report. *Int J Surg Case Rep.* 2017;38:37-42. doi:10.1016/j.ijscr.2017.04.027
5. Lim YW, Chang YJ, Kwon SY, Kim YS. A simple method using a PACS to minimize leg length discrepancy in primary THA. A method to minimize leg length discrepancy. *J Arthroplasty.* 2013;28(10):1791-1795. doi:10.1016/j.arth.2013.02.022
6. Chan KC, Gill GS. Cemented hemiarthroplasties for elderly patients with intertrochanteric fractures. *Clin Orthop Relat Res.* 2000;(371):206-215. doi:10.1097/00003086-200002000-00025
7. Qi X, Zhang Y, Pan J, Ma L, Wang L, Wang J. Effect of Bone Cement Implantation on Haemodynamics in Elderly Patients and Preventive Measure in Cemented Hemiarthroplasty. *Biomed Res Int.* 2015;2015. doi:10.1155/2015/568019
8. Amstutz H, Mai L, Schmidt I. Results of interlocking wire trochanteric reattachment and technique refinements to prevent complications following total hip arthroplasty. *Clin Orthop Relat Res.* 1984;(183):82-89.
9. Barrack RL, Butler RA. Current status of trochanteric reattachment in complex total hip arthroplasty. *Clin Orthop Relat Res.* 2005;(441):237-242. doi:10.1097/01.blo.0000191274.42410.40
10. Boardman K, Bocco F, Charnley J. An evaluation of a method of trochanteric fixation using three wires in the Charnley low friction arthroplasty. *Clin Orthop Relat Res.* 1978;(132):31-38.
11. Aktseles I, Kokoroghiannis C, Fragkomichalos E, et al. Prospective randomised controlled trial of an intramedullary nail versus a sliding hip screw for intertrochanteric fractures of the femur. *Int Orthop.* 2014;38(1):155-161. doi:10.1007/s00264-013-2196-7
12. Babst R, Renner N, Biedermann M, et al. Clinical results using the trochanter stabilizing plate (TSP): the modular extension of the dynamic hip screw (DHS) for internal fixation of selected unstable intertrochanteric fractures. *J Orthop Trauma.* 1998;12(6):392-399. doi:10.1097/00005131-199808000-00005
13. Madsen J, Naess L, Aune A, Alho A, Ekeland A, Strømsøe K. Dynamic hip screw with trochanteric stabilizing plate in the treatment of unstable proximal femoral fractures: a comparative study with the Gamma nail and compression hip screw. *J Orthop Trauma.* 1998;12(4):241-248. doi:10.1097/00005131-199805000-00005
14. Rodop O, Kiral A, Kaplan H, Akmaz I. Primary bipolar hemiprosthesis for unstable intertrochanteric fractures. *Int Orthop.* 2002;26(4):233-237. doi:10.1007/s00264-002-0358-0

## Acknowledgment

The authors would like to thank all the staff of Gadjah Mada University Academic Hospital for their help in collecting data.