



Modified Stoppa Approach for Concomitant Anterior and Posterior Pelvic Ring Fractures: A Case Report

Arif Wibowo¹, Mohammad Zaim Chilmi²

¹Fellow of Adult Reconstruction, Trauma and Sport, Indonesian Hip and Knee Society, Dr. Soetomo General Hospital, Surabaya, Indonesia

²Department of Orthopaedic and Traumatology, Universitas Airlangga, Dr. Soetomo General Hospital, Surabaya, Indonesia

ABSTRACT

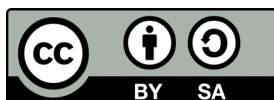
Background : The modified Stoppa approach was performed to access the site of anterior column fracture rather than the ilioinguinal approach to decrease morbidity.

Case Summary: A 24-year-old female suffered a serious traffic accident when she was riding a motorcycle. While colliding with a car from the front, she fell off after attempting to dodge a hole on the road. Then, the patient was dragged beneath a moving car after falling. Several hours later at the hospital, she was diagnosed with closed pelvic fractures of right superior and inferior pubic rami with right sacroiliac joint disruption, and a closed fracture of right shaft femur. After improvement of her condition in the ward, open reduction and internal fixation for the femoral fracture and for the pelvic fractures were performed using a modified Stoppa approach to access the fracture site.

Conclusion: Modified Stoppa approach is suitable for treating anterior column fractures. In this case, sufficient exposure of the pelvic fracture could be achieved and were conveniently reduced, while achieving less complication and resulting in a satisfactory curative effect.

Keywords: *Pelvic fracture, Modified Stoppa approach, Direct Access, Case Report*

Level of Evidence : IV



This is an open access article under the CC-BY-SA license.

Article History

Submission : July 7th, 2021
Revision : January 24th, 2022
Accepted : February 4th, 2022

Corresponding Author

Mohammad Zaim Chilmi, MD, PhD
Department of Orthopaedic and Traumatology, Faculty of Medicine, Universitas Airlangga, Dr. Soetomo General Hospital, Jl. Mayjend Prof. Dr. Moestopo No. 6-8, Airlangga, Surabaya 60286, Indonesia.
e-mail: chilmi.orth@yahoo.co.id

Introduction

Nowadays, with the rapid developments in modes of transportation and human mobility, the incidence rate of fractures continues to increase as a result of high energy impact injuries such as those caused by traffic accidents. Pelvic fractures due to these accidents are among the most complicated and challenging. Generally, pelvic fractures from vehicular accidents and similar sports-related injuries can involve serious complications including extensive internal bleeding and the possibility of compound fractures to adjacent bones. These types of injuries require complex decisions concerning surgical techniques and prosthesis involving novel implants, staged approaches to access the injured sites and for many patients, the prognosis is poor.¹

Due to the complexity of the anatomy and limitations of laparoscopic surgery in many facilities, patients with pelvic fractures can present with many challenges. In the patient with displaced pelvic fractures, aggressive surgical treatment is recommended with an appropriate operative approach to expose the fracture exposure and allow for reduction techniques to be attempted.² There are several advantages that have been noticed in the treatment of pelvic fractures by using the modified Stoppa approach including less trauma, acceptable and quick exposure, accessible and efficient fracture reduction and fixation, with reduced complications and improved postoperative recovery.¹

First reported in 1975 by Rene Stoppa for hernia repair surgery, the Stoppa approach was also used for the treatment of inguinal hernias by Rives et al. Later, a modification to this Stoppa approach was reported by Hirvensalo et al. in 1993 and Cole and Bolhofner in 1994, both independently use it for fixation of pelvic acetabulum fractures using intrapelvic extraperitoneal approaches.^{3,4} Among its several advantages, the modified Stoppa approach provides direct access to the pubic bones, posterior surface of the ramus, pubic eminence, quadrilateral surface

and the infrapectineal surface, in addition to the anterior sacroiliac joint, sciatic notch and sciatic buttress.⁵

Since it is used more often, there are more extensive reports concerning the ilioinguinal approach and its outcomes. Some of the reported challenges in the traditional ilioinguinal approach include more intricate anatomy, serious trauma, limited space for fracture reduction and fixation, and possibility of additional complications.¹

Case Presentation

A 24-year-old female was admitted in our hospital with the chief complaints of pain from severe pelvic injuries sustained while colliding with a car in a motorcycle accident. History taking revealed she had suffered a serious traffic accident when she collided with a car from the front and fell off when dodging a hole on the road. Then, the patient was dragged beneath a moving car after falling.

Several hours after the accident at the Emergency Room, the patient received basic life support treatment. The patient has a history of being free from previous medication. During the physical examination, the patient exhibited right hip tenderness, deformity on the right femur and limitation of motion due to pain. There were no apparent vessel, nerve, nor pelvic organ injuries.

The patient underwent pelvic x-ray film radiography: AP and lateral, inlet, outlet view, and pelvic computerized tomography (CT)-scans for three-dimensional reconstructions. She was diagnosed as closed pelvic fracture of right superior and inferior pubic rami with right sacroiliac joint disruption, and a closed fracture of right shaft femur.

The patient underwent external fixation in the Emergency Room operating theater. After her condition showed improvement in the ward, open reduction and internal fixation for the femoral fracture and for the pelvis fracture were performed using a modified Stoppa approach to access the fracture site.

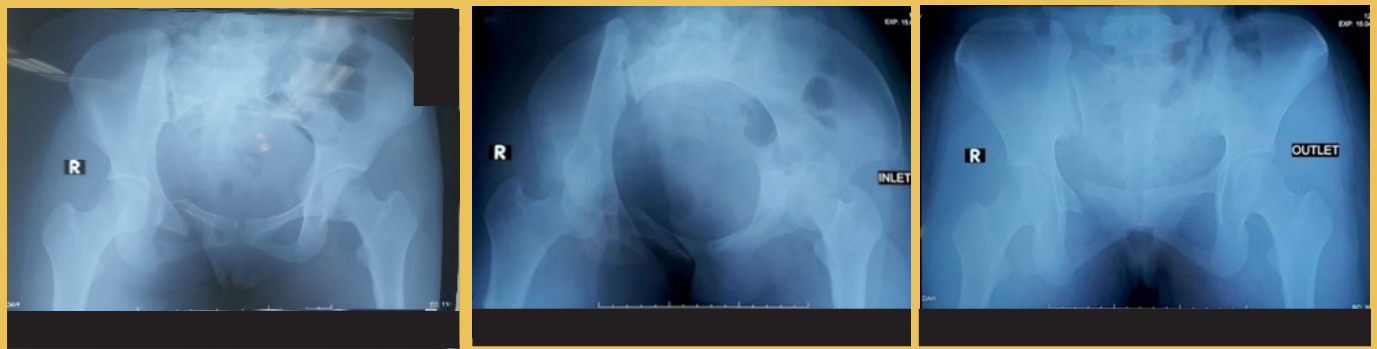


Figure 1. Preoperative plain radiography: AP Lateral, inlet and outlet views showed closed pelvic fracture of right superior and inferior pubic rami and right sacroiliac joint disruption.

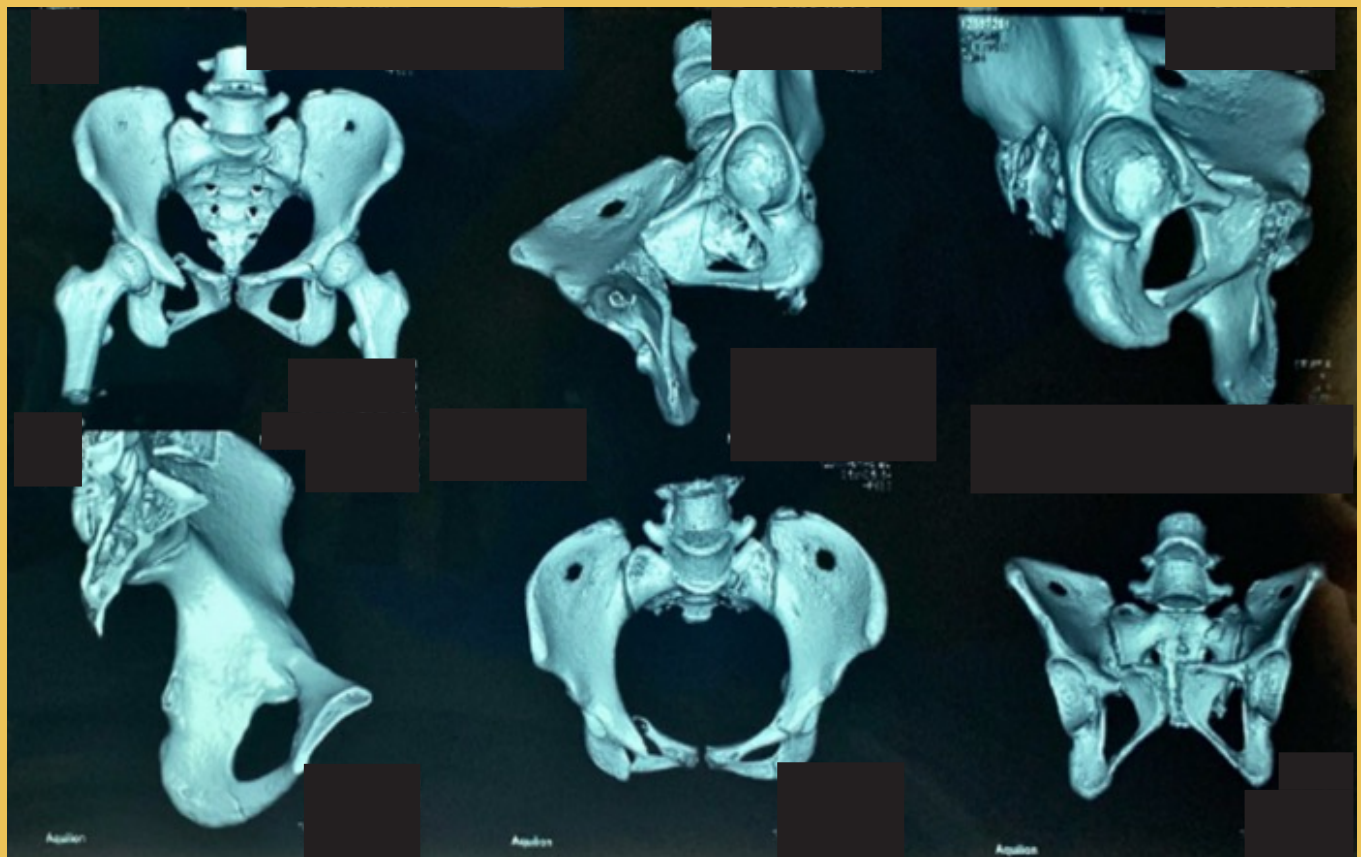


Figure 2. Preoperative three-dimensional reconstructions CT scan.

Operative Technique

Following previously described procedures, the surgery was performed under general anesthesia. The patient was positioned supine on the operating table, the lower abdomen was then aseptically draped for the operation. Hip flexion was achieved by placing a large sandbag underneath the knee.

This position relaxed the iliopsoas muscle, the abdominal muscles and also the external iliac/femoral neurovascular bundle. This position also permitted a multi-directional traction of the limbs needed to reduce the fracture. The surgeon positioned himself on the contralateral side of the injured pelvic.⁶

We identified the superior pubic ramus and 1 cm proximal to it performed a Pfannenstiel skin incision of 12–15. We then deepened the incision, until the abdominal fascia was exposed. As the modified Stoppa approach alone was inadequate to attain proper reduction and fixation, an additional lateral window was made along the iliac crest. Both were needed to fix the sacroiliac joint disruption.^{1,6,7}

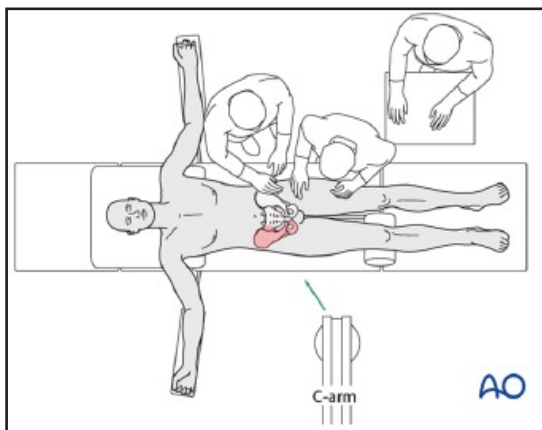


Figure 3. The patient is positioned supine. The surgeon stands contralateral to the fracture site, behind them, stands the scrub team, while the image intensifier is placed ipsilateral to fracture site.⁷

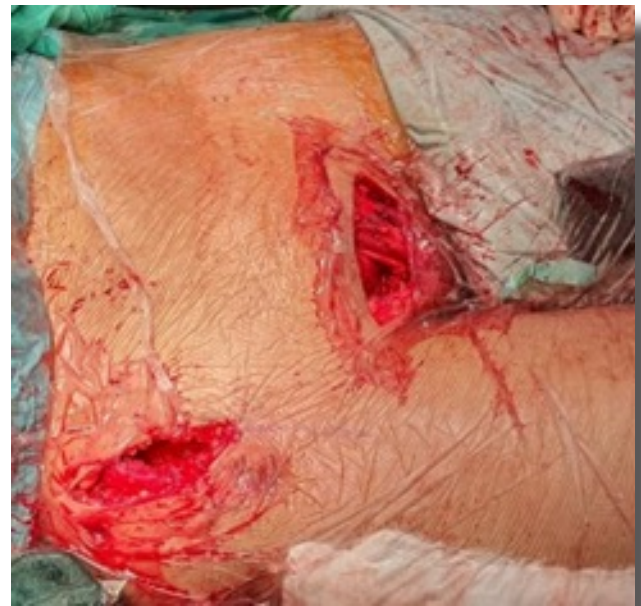

Figure 4. Lateral and Pfannenstiel incision.

After we exposed the rectus abdominis muscle, it was split along the linea alba so that we could proceed into the internal aspect of the pelvis. As we approached the inside of the pelvis, first we identified and then ligated the corona mortis.

Corona Mortis was formed by arterial anastomotic branches between obturator artery and the inferior abdominal, along with their accompanying veins. All of these vessels of the "corona mortis" should be isolated and cut off. Subperiosteal dissection was performed along the pelvic brim to expose the fracture fragments.^{1,6,7}

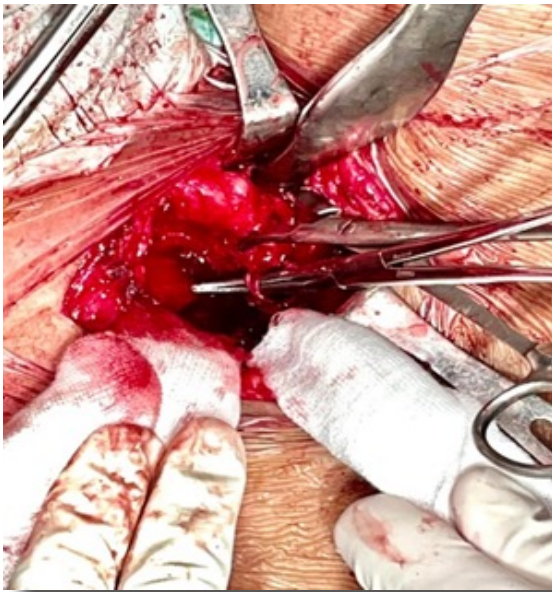


Figure 5. Corona mortis was identified.

The obturator nerve and vessels were usually identified easily as they pass through the obturator foramen. They should be protected during the further procedure. As the iliopsoas was retracted upwards, do be careful not to damage the external iliac artery and vein lying over it. In some risky cases, intraoperative damage may befall at the external iliac vein. Once appropriate exposure of the fracture site was achieved, we attempted to reduce the fracture, followed by internal fixation.^{1,6,7}

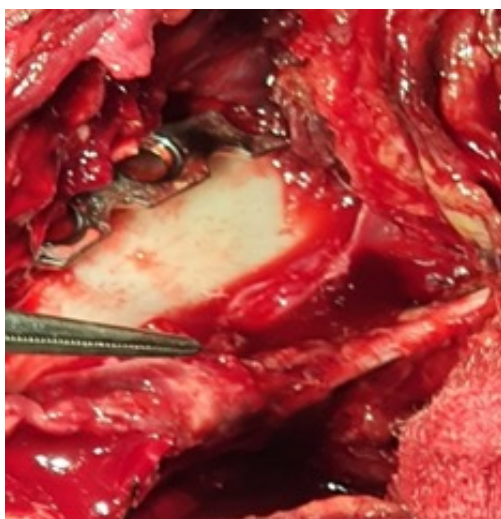


Figure 6. N. Obturator clearly identified.

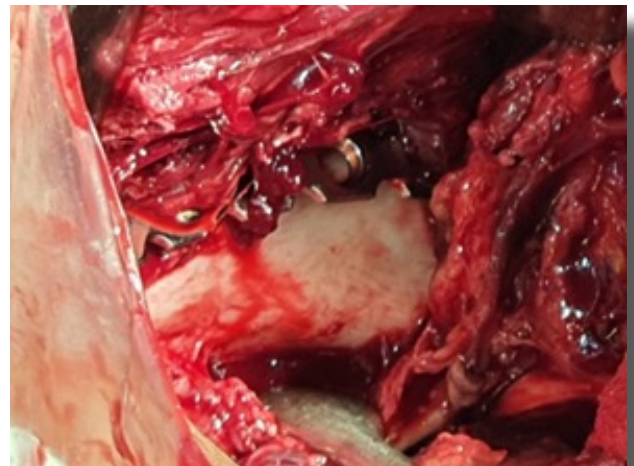


Figure 7. Direct access to the quadrilateral surface and exposed clearly.

Connecting Lateral window to Medial Window using Cobb. The fractures were reduced with pelvic fracture reduction forceps.

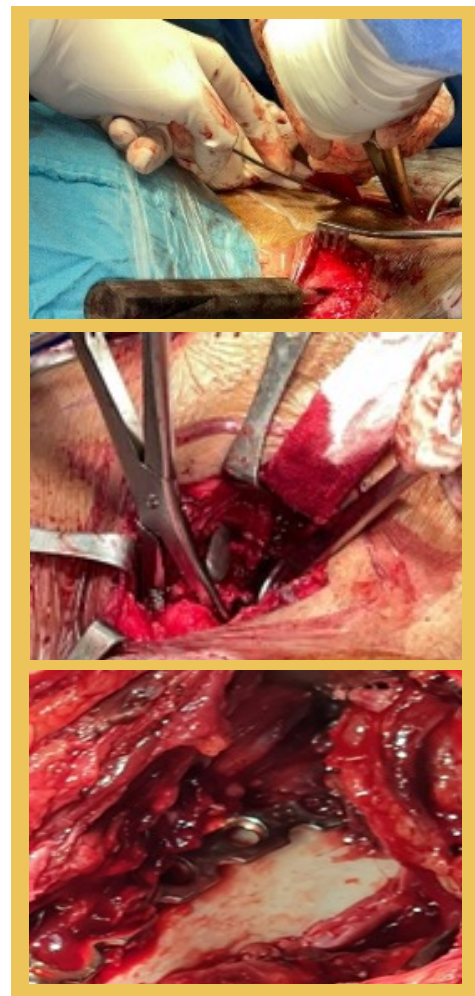


Figure 8. Reduction and plate placement.

Intraoperative examination using C-arm fluoroscopy was needed to observe fracture reduction, as well as the screws position and length in the steel, especially to ensure the acetabulum was not breached. Reduction and fixation of the sacroiliac joint disruptions were then attempted, combined with the iliac fossa approach.

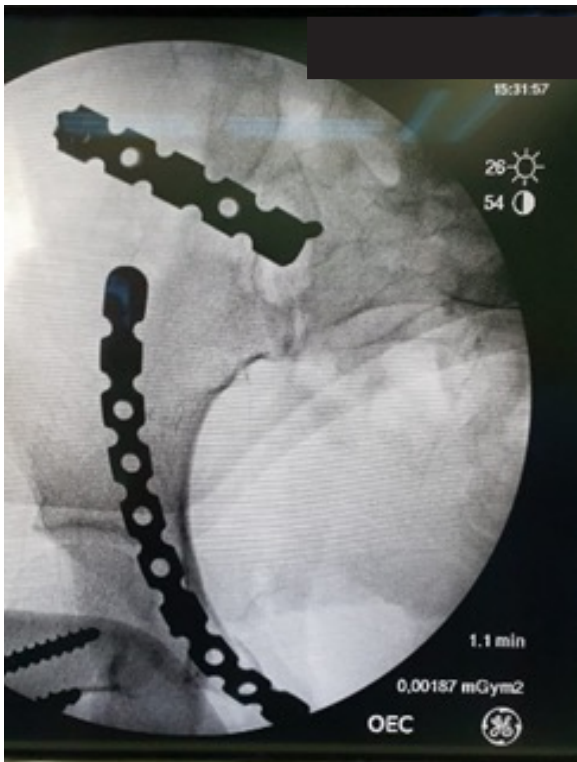

Figure 9. Intraoperative Image intensifier

It is important to check the peritoneum integrity, followed by placement of a negative pressure drainage tube at the retropubic space, the inner side or the posterior of the acetabulum. We closed the midline incision in the rectus abdominis and superficial tissues in layers with precaution not to injure the underlying bladder and peritoneum.

While closing the lateral window, it was important to do it in layers with reconstruction of the previously preserved fascial layer. Then, closely sutured the fascia recta, and finally the skin.^{1,6,7}

Discussion

To reach the goal of early functional exercise, the main aims of the above-described procedures in pelvic fracture surgeries include correction of any deformities and restoration of the pelvic ring structure stability. In the step-wise process, some modifications of previous approaches can be done to help in reducing pelvic fractures, and providing reliable fixations. The challenging difficulties with these surgical approaches involving accessing the pelvic fractures with efforts at reduction and internal fixation are due to the intricate anatomical structure and its profound location. Accordingly, a thorough radiographic analysis is needed to best decide the suitable preoperative plan, including the reduction order and fixation method chosen. This in turn will influence the surgical field that has to be secured.

The traditional ilioinguinal approach has several advantages, including possible exposure of the whole anterior ring of the pelvis, in addition to the transverse fracture and anterior acetabular fractures, thereby reducing the incidence of heterotopic ossification and sciatic nerve injury.

Nevertheless, the approach is complex with complicated anatomical structures, while it is necessary to expose any fractures need in three windows of tissue spaces: the external iliac lymph vascular bundle, the femoral nerve, and the spermatic cord or the fallopian arch.

The chance of additional trauma during surgery is high, and an even higher technique is required, since damages could occur to important tissues and cause other defects.¹ Among various structures, the ilioinguinal approach most frequently injure the lateral femoral cutaneous nerve. Previous review identified that excessive retraction or severing of the surgical window might cause nerve injury.⁷ The modified Stoppa approach which is now better known as Anterior Intra Pelvic approach, does not expose the middle window, reducing the chance of -

injuring the femoral nerve, inguinal canal, and external iliac vessels.

The modified Stoppa approach is superior as it allows direct visualization of the entire pelvic brim from the pubic body to the anterior aspect of the sacral ala, direct visualization and access to the quadrilateral plate essential for reduction and plating, and direct visualization and access to the posterior column from the greater sciatic notch to the ischial spine necessary for reduction and plating.⁷

In comparison to the ilioinguinal approach, the modified Stoppa approach could have lesser blood loss, decreasing the amount of blood transfusion, and shortening the operation time. While inguinal approach has an inherent risk of injuring the iliac vein and the lateral femoral cutaneous nerve, the modified Stoppa approach has no requirements of exposure and traction on the above tissues, so no damages would occur in these areas.¹

Nonetheless, the modified Stoppa approach needs significantly more delicate dissection, especially in the presence of intrapelvic adhesions, such as revision surgery including implant removal, and previous surgery in the lower abdomen.

In comparison to the other pelvic approaches, performing the modified Stoppa approach is easier in patients with a thin body type. The modified Stoppa approach is therefore relatively contraindicated in severely obese patients or those with previous repeated pelvic surgery.^{1,6,7}

Conclusions

The modified Stoppa approach is appropriate for treating pelvic fractures as it has less trauma, acceptable and quick exposure, accessible and efficient fracture reduction and fixation, with reduced complications and improved postoperative recovery.

References

1. Hong-Zhang Guo, Yu-Fang He, Wan-Qing He. Modified Stoppa approach for pelvic and acetabular fracture treatment. *Acta Orthop Bras*. 2019;27(4):216-9.
2. Elmadağ M, Güzelb Y, Acarc MA, Uzera G, Arazi M. The Stoppa approach versus the ilioinguinal approach for anterior acetabular fractures: a case control study assessing blood loss complications and function outcomes, *Orthopaedics & Traumatology: Surgery & Research*. 2014;100:675-680.
3. Hirvensalo E, Lindahl J, Böstman O. A new approach to the internal fixation of unstable pelvic fractures. *Clin Orthop Relat Res*. 1993;(297):28-32.
4. Soni A, Gupta R, Sen R, Modified Stoppa approach for acetabulum fracture: a review, *Rev Bras Ortop*, 2019;54:109-117.
5. Lindahl J and Hirvensalo E. Surgical treatment of pelvic ring fractures. *Suomen Ortopedia ja Traumatologia*. 2008;31.
6. Ferguson T, Forward D, Modified Stoppa Approach, AO Foundation Course, 2020
7. Ha Yong Kim, Dae Suk Yang, Chang Kyu Park, Won Sik Choy. Modified Stoppa approach for surgical treatment of acetabular fracture. *Clinics in Orthopedic Surgery*. 2015;7:29-38.